

Periprocedural and late complications after percutaneous closure of patent foramen ovale: a single centre experience

Przemysław Węglarz¹, Ewa Konarska-Kuszevska¹, Katarzyna Spisak-Borowska²,
Jerzy Machowski², Agnieszka Drzewiecka-Gerber¹, Piotr Kuszevski³, Christopher L. Jackson⁵,
Grzegorz Opala⁴, Maria Trusz-Gluza¹

¹1st Department of Cardiology, Medical University of Silesia, Katowice, Poland

²Department of Neurology, Oswiecim, Poland

³Medical University of Silesia, Katowice, Poland

⁴Department of Neurology, Medical University of Silesia, Katowice, Poland

⁵Bristol Heart Institute, Bristol University, Bristol, Great Britain

Abstract

Background: Patent foramen ovale (PFO) is a potential risk factor for ischaemic stroke in young individuals. An interventional method of secondary stroke prevention in PFO patients is its percutaneous closure.

Aim: To assess safety and effectiveness (i.e. lack of residual shunt) of percutaneous PFO closure in patients with history of cryptogenic cerebrovascular event.

Methods: 149 patients (56 men/93 women), aged 39 ± 12 years, underwent percutaneous PFO closure. The implantation was performed under local anaesthesia, guided by trans-oesophageal echocardiography (TEE) and fluoroscopy. Follow-up trans-thoracic echocardiography (TTE) was performed at 1 month and follow-up TEE at 6-months. In cases of residual shunt, additional TEE was performed after ensuing 6 months.

Results: Effective PFO closure (no residual shunt) was achieved in 91.3% patients at 6 months and 95.3% patients at 12 months. In 2 patients transient atrial fibrillation was observed during the procedure. In 2 patients, a puncture site haematoma developed and in 1 patient superficial thrombophlebitis was noted. In 1 patient a small pericardial effusion was observed, which resolved at day 3 post-procedurally, after administration of non-steroidal anti-inflammatory drugs.

Conclusions: Percutaneous PFO closure seems to be a safe procedure when performed in a centre with adequate expertise with regard to these procedures.

Key words: patent foramen ovale, PFO, complications, closure procedures

Kardiol Pol 2012; 70, 5: 478–484

INTRODUCTION

The occurrence of ischaemic stroke or transient ischaemic attack (TIA) in young individuals can be related to the presence of patent foramen ovale (PFO) [1]. Despite the lack of unequivocal recommendations with regard to PFO closure in patients with cryptogenic embolic episode of putative para-

doxical mechanism, these procedures are currently performed routinely in many cardiovascular centres [2–4].

In the majority of literature to date, this treatment strategy is considered safe as well as effective in terms of preventing recurrences of cerebral or peripheral embolic episodes [5, 6]. A series of randomised clinical studies were underta-

Address for correspondence:

Przemysław Węglarz, MD, PhD, 1st Department of Cardiology, Medical University of Silesia, ul. Ziołowa 45/47, 40–635 Katowice, Poland, e-mail: pweglarz@gmail.com

Received: 05.06.2011 Accepted: 02.11.2011

Copyright © Polskie Towarzystwo Kardiologiczne

ken aiming at comparison of pharmacological treatment and percutaneous PFO closure in patients for secondary prevention of cryptogenic stroke. The majority of these studies are still recruiting patients. In November 2010 the results of the first prospective, randomised multi-centre CLOSURE-I study were presented. A relatively high percentage of complications and procedural failure was recorded in this study. This in turn could have influenced the results including the observed lack of advantages of percutaneous PFO closure procedures over pharmacological treatment in the prevention of ischaemic events.

The aim of this prospective evaluation was to assess safety and effectiveness (defined as lack of residual shunt) in patients with history of cryptogenic cerebrovascular event.

METHODS

Study population

Out of 304 patients with cryptogenic TIA/ischaemic stroke, diagnosed in the 1st Department of Cardiology, Upper-Silesian Cardiology Centre, Silesian Medical University in the years 2004–2008, PFO was confirmed in 224, and in 149 PFO closure was subsequently performed. Mean age of the patients was 18–60 years, median 38 years. Clinical characteristics of the study group and the data on cerebrovascular events that prompted the intervention are presented in Tables 1 and 2, respectively.

Hypertension was diagnosed when blood pressure values exceeded 140/90 mm Hg or when on blood pressure lowering medication. Hyperlipidaemia was diagnosed when total cholesterol exceeded 200 mg/dL or when on hypolipemising medication. Diabetes was diagnosed when fasting glucose reading exceeded 126 mg/dL, random glucose reading exceeded 200 mg/dL or when on antidiabetic medication or taking insulin.

Criteria for and against PFO closure

Inclusion criteria for percutaneous PFO closure included: history of cryptogenic stroke and/or TIA, patient age (< 65 years), the presence of PFO (as confirmed by positive contrast transoesophageal echocardiography [TEE]), patient consent for the procedure.

In addition, in the decision-making as to whether to perform the procedure the following were considered: factors suggesting the relationship of the event with PFO such as thrombophlebitis, post-exertion, dehydration, pelvic surgery, location of lesions on neuroimaging study (multiple diffuse ischaemic lesions, lesions within the posterior cerebral vascular territory), PFO anatomy (e.g. the presence of inter-atrial septal aneurysm or Chiari network), exclusion of other potential risk factors of cerebrovascular ischaemic events.

Criteria disqualifying patients from PFO closure included: expected life span of less than 2 years, identifiable cause of stroke other than PFO (e.g. thrombus or vegetation wi-

Table 1. Clinical characteristics of patents in whom PFO closure was performed

Sex (females)	93 (62%)
Hypertension	35 (23.5%)
Diabetes	0 (0%)
Smoking	24 (22.8%)
Hipercholesterolaemia	42 (28.1%)
Atrial fibrillation	0 (0%)
Oral contraceptives	25 (16.8% women)
Calf varicose veins	20 (13.4%)
Migraine without aura	16 (10.7%)
Migraine with aura	46 (30.9%)

Table 2. Cerebrovascular events in patients qualified for PFO closure

Ischaemic stroke	31%
Ischaemic stroke + TIA	30%
> 1 TIA	34%
> 1 ischaemic stroke	5%

TIA — transient ischaemic attack

thin cardiac chambers), atherosclerotic plaque in extra-cranial arteries, aortic arch or ascending aorta, congestive heart failure, bacterial endocarditis, significant mitral valvular lesion, atrial fibrillation, intolerance of medication required during the procedure or post-procedurally, lack of patient's consent.

PFO patients in whom the procedure was not performed during the study period had the closure performed at a later date or are followed-up. On the other hand, 80 patients in whom PFO was excluded remained under neurological surveillance. No patient in the study group with confirmed PFO was unequivocally disqualified from the intervention.

PFO diagnosis

All patients had initial biochemical workup, ECG and 24-h Holter ECG monitoring, trans-thoracic echocardiography (TTE) and TEE were performed in all patients. Subsequently, the decision with regard to percutaneous PFO closure was made.

TEE study was carried out on Vivid 7 system (GE, Norway) with multi-planar trans-oesophageal probe, according to recommendations published by the Working Group of European Society of Cardiology in 2001. At the first stage of TEE, causes of ischaemic events other than PFO were being excluded, by assessing the following structures: ascending aorta, mitral and aortic valves, left atrium and left atrial appendage, left ventricle and right atrial anatomical structures and inter-atrial septum (atrial septal aneurysm or Chiari ne-

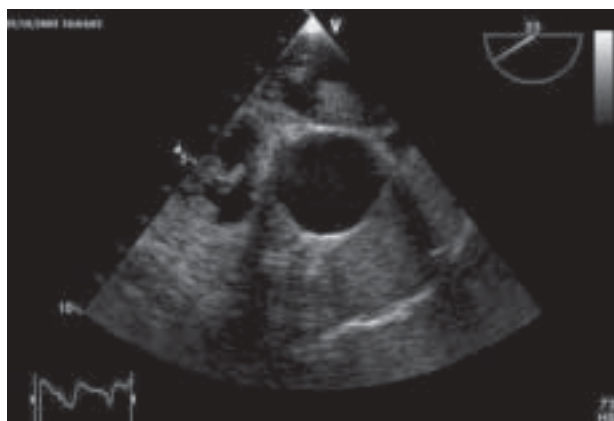


Figure 1. Massive contrast passage (air microbubbles) through PFO on trans-oesophageal echocardiography

Table 3. PFO-associated findings on trans-oesophageal echocardiography

Atrial septal aneurysm	73 (49%)
Chiari network	23 (15.4%)
PFO — large shunt	88 (59.1%)
PFO — intermediate shunt	45 (30.2%)
PFO — small shunt	16 (10.7%)

network). Then, contrast was administered in the antecubital vein. The contrast was prepared by mixing 9 mL of 0.9% NaCl with 1 mL air between two 10 mL syringes. Each patient had to perform the Valsalva manoeuvre prior to the study to ascertain that the test itself will be effective. The test was termed positive if the thin part of the inter-atrial septum moved from right to left. Contrast passage was assessed before, during and after the Valsalva manoeuvre. The test result was expressed in the range of 0–3, where 0 denoted no passage of the contrast bubbles into the left atrium, 1 — denoted a passage of a few contrast bubbles into left atrium, 3 — denoted a cloud of contrast bubbles passing to the left (Fig. 1) and 2 — denoted an amount of contrast bubbles that was intermediate between 1 and 3 [7, 8].

Atrial septal aneurysm was diagnosed when partial swing of the atrial septum (at least 10 mm towards the right or left atrium of at least 10 mm amplitude towards one side or a sum of 15 mm both sides) was observed [9]. Table 3 contains the results of PFO assessment in TEE.

PFO closure

All the PFO closure procedures were performed in the Department of Invasive Cardiology, 7th Independent Public University Hospital, Silesian Medical University, by 1 operator. Before the procedure the patients were administered 1.0 g

cephazoline i.v. and then 2 subsequent doses were repeated within 12 h period.

The procedure was performed under local anaesthesia, and the vascular access was achieved by the femoral vein puncture and a short 6 F sheath placement. With use of a multipurpose diagnostic catheter, under fluoroscopic guidance, PFO channel was cannulated and left atrium entered, with the catheter tip placed in 1 of the pulmonary veins. The PFO cannulation was confirmed by TEE. The subsequent stages of the procedure, including the occluder implantation, did not require continuous echocardiographic guidance. Trans-catheter heparin at the dose of 5000 U was administered.

The diagnostic catheter was exchanged for a long Amplatzer guidewire with a soft tip over which a trans-septal sheath was introduced (9–12 F depending on the occluder type) with the tip left in the left atrium (Fig. 2A). The system was perfused with normal saline and heparin to avoid thrombosis during device placement.

After occluder preparation, including repeated flush of the system folded within the sheath, aiming at elimination of the air bubbles, it was advanced into the trans-septal sheath and the right atrial part was opened (Fig. 2B).

The system placement was guided by fluoroscopy and by TEE. After the correct occluder position was confirmed, the introducing system was disconnected (Fig. 2C).

During the procedure, no additional techniques such as trans-septal puncture in case of a tunnel-shaped PFO were used.

In the assessment of the procedural safety, peri-procedural complications were recorded over 24 h. Major complications included: death, stroke, loss of device, device thrombosis, perforation of the cardiac or vascular wall, cardiac tamponade and air embolism.

After the procedure all the patients were given 150 mg aspirin daily and 75 mg of clopidogrel for 6 months and infective endocarditis prophylaxis was recommended for 1 year. One day after the procedure 12-lead ECG was recorded, blood count taken and TTE performed in order to assess the device position and to exclude pericardial effusion. After 1 month, TTE was repeated.

Six months after the procedure, follow-up TTE and TEE were performed, in order to assess the device position, device thrombosis or possible residual shunt. Effective PFO closure was defined as the absence of residual shunt in contrast TEE performed at 6 months post-procedurally. In cases of confirmed residual shunt, another TEE was performed after the next 6-month period. The residual shunt was termed small when only 1–5 bubbles passing through the septum were noted, intermediate when 6–20 bubbles were observed and large in cases where more than 20 bubbles were noted in the left atrium.

All the patients remained under continuous neurological follow-up. Late cerebrovascular events such as stroke or TIA as diagnosed by a neurologist were recorded.

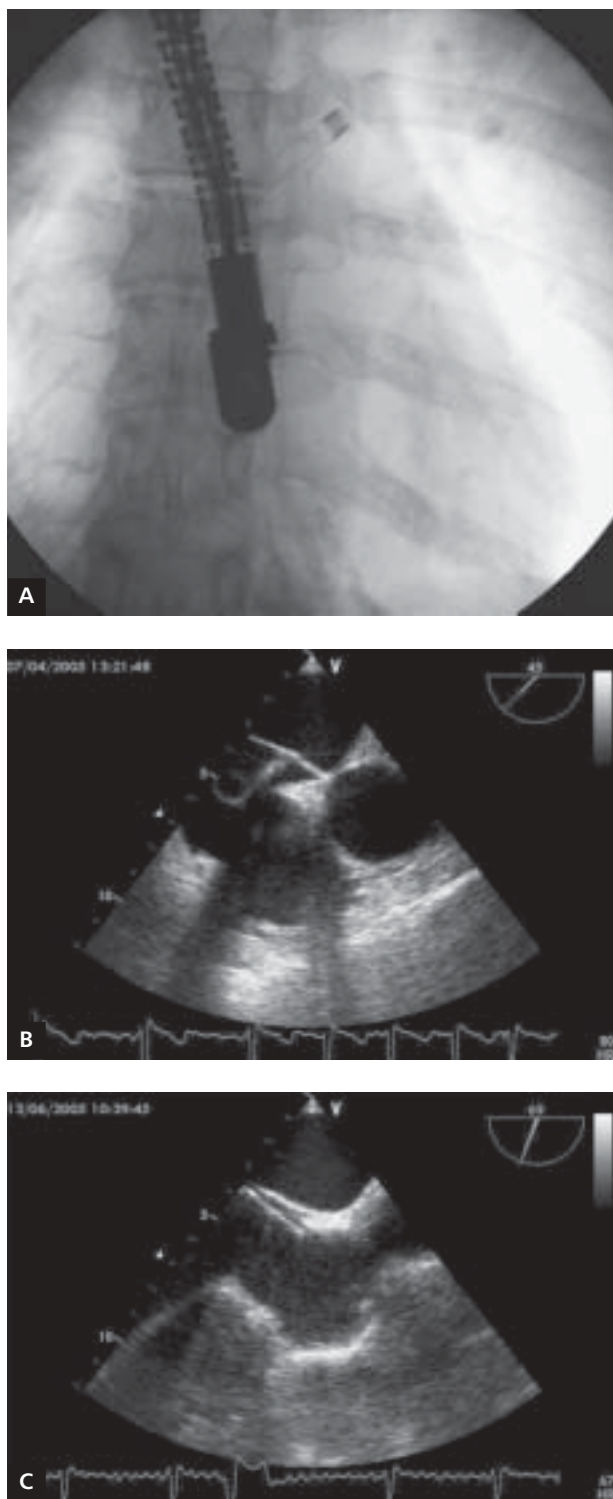


Figure 2. A. Transseptal sheath introduced via PFO to the left atrium; B. Left-sided Intrasept (CARDIA) occluder disc after opening in the left atrium on trans-oesophageal echocardiography (TEE); C. Intrasept occluder sealing the PFO immediately after implantation (TEE)

Table 4. Periprocedural complications

All complications, including:	6 (4%)
Atrial fibrillation	2 (1.3%)
Pericardial effusion	1 (0.6%)
Femoral access site haematoma	2 (1.3%)
Superficial thrombophlebitis	1 (0.6%)

RESULTS

In all patients the procedure of occluder implantation was successfully completed. A total of 149 occluders were implanted, including 107 Cardia devices (99 Intrasept and 8 Atrisept), 40 Occlutech Figulla devices, 1 Amplatzer PFO occluder and 1 Starflex PFO Star.

In the periprocedural 24-h period no major complications were recorded. In 6 (4%) patients small complications were observed that are summarised in Table 4. In 2 patients atrial fibrillation occurred that spontaneously reverted to sinus rhythm within 12 h post-procedurally. A minor haematoma at the site of femoral vein puncture was noted in 2 patients and in 1 superficial thrombophlebitis occurred. Small pericardial effusion was found on echocardiography in 1 patient. After administration of non-steroidal anti-inflammatory drugs the effusion resolved within 3 days.

Mean follow-up was 24.6 months (median 19). No patient deaths were recorded. Effective PFO closures (i.e. with no residual shunt), as assessed on TEE with intravenous contrast administration and the Valsalva manoeuvre, was achieved in 91.3% patients at 6 months and in 95.3% patients at 12 months (Table 5).

In 13 patients in whom residual shunt was observed, the device was Cardia Intrasept system in 12 cases, and in 1 case an Occlutech Figulla system. Residual shunt analysis in patients with different occluders is presented in Table 6.

In 2 (1.3%) patients with implanted Intrasept occluders (Cardia) device thrombosis was recorded on follow-up TEE. After administration of vitamin K antagonists for 8 weeks, no thrombosis was found on control TEE. During the entire follow-up period no symptoms or recurrent cerebrovascular events were recorded in these patients.

DISCUSSION

Rapid advances in technology resulted in the development of easily implantable occluders for PFO closure, which allow for increasing procedural success rates as well as reduced complications. Reported rates of residual shunt after percutaneous PFO closure are inconsistent and range from 4% to 49% [10–12]. In earlier publications Windecker et al. [12] found residual shunt in as many as 27% out of 80 patients at 6 months after the procedure. Schwerzmann et al. [13] noted significant differences between residual shunt rates assessed on contrast TEE in patients with Amplatzer as compared with Cardia systems. Six

Table 5. Residual shunt in long term follow-up

Shunt	Total	Small	Intermediate	Large
At 6 months	13 (8.7%)	10 (6.7%)	1 (0.67%)	2 (1.3%)
At 12 months	7 (4.7%)	4 (2.6%)	1 (0.67%)	2 (1.3%)

Table 6. Residual shunt and the occluder type

Occluder type	Cardia — Intrasept	Occlutech — Figulla	P
Number of implanted devices	99	40	–
Number of residual shunt cases at 6 months	12	1	0.15

months after the procedure, complete closure was found in 94% of patients with Amplatzer devices and only 66% of patients in whom PFO STAR system was used. In another study published in 2006 which included 407 patients with implanted PFO STAR device, residual shunt at 6 months was observed only in 10.8% [2]. The smaller rate of residual shunt is probably due to the fact that newer generation of device was used. In a study published in 2009, Wahl et al. [3] achieved complete closure in 91% of 620 PFO patients.

During the 2010 American Heart Association Congress the results of CLOSURE I study were announced. The study included 909 patients who were randomised to PFO closure with STARFlex (NMT Medical) followed by 6-month therapy with aspirin plus clopidogrel or to pharmacotherapy with aspirin, warfarin or both. Interventional arm included 447 patients. Effective closure was performed in 402 patients (periprocedural success rate 90%) which seems rather low compared to the results in our group, in which the device was successfully implanted in all qualifying patients. Absence of residual shunt was found in 86.1% at 6 months, 86.4% at 12 months and 86.7% after 2 years of follow-up. In our group, 95.3% patients were free from residual shunt at 12 months.

In a retrospective meta-analysis of Khairy et al. [5] which included 10 studies on percutaneous PFO closure, the complications were divided into minor and major, occurring in 7.9% (0–24%) and 1.5% (0–10%) of the patients, respectively. Braun et al. [10] in a study of 307 patients recorded periprocedural complications in 3% of the study population, including 2% patients with minor (ST-segment elevation in 5 patients, arterio-venous fistula in 1 patient) and 1% major complications (TIA in 2 patients and device dislodgement in 1 patient).

On the other hand, Post et al. [4] in a study of 112 patients observed minor complications in 7.1% patients (transient arrhythmia, femoral access site haematoma), and major in 1.8% patients. In the study by Windecker et al. [12] including 80 patients, as much as 10% of patients had major periprocedural complications (device thrombosis, cardiac tamponade, stroke).

Our results with regard to safety were similar or even more favourable than the other results published to date. Peri-procedural complication rate was 4%, but contrary to many previous reports no major complications were recorded. The minor complications that were observed in our patients were transient and only in the patient with pericardial effusion prolonged hospitalisation was necessary.

One of the most serious complications is device thrombosis. Data on the rate of such adverse event ranges from 3% to 27% [14, 15]. In particular, the left sided thrombosis threatens with recurrence of the ischaemic thromboembolic event. This complication has rarely been described with regard to Amplatzer devices [10, 15]. In umbrella-shaped devices such as CardioSEAL, the thrombosis most frequently occurs on nitinol arms or on the posterior surface of the central part of the device [16].

In a study by Braun et al. [17] in which Cardia occluders were used, device thrombosis was found in 8 (2.9%) patients. In the aforementioned CLOSURE I study, 4 (1%) cases of device thrombosis were recorded. We observed similar results with regard to Cardia occluders. In 2 (1.3%) patients a small thrombus on the occluder was observed. In both patients 6-month treatment with oral vitamin K antagonist (acenocumarol) was recommended and on follow-up TEE after 6 months no thrombus was found. Also no stroke or TIA were observed in these patients during follow-up. It seems that the use of occluders made of materials that are vinyl alcohol derivatives can be related to increased risk of device thrombosis.

Unexpectedly high failure rate in PFO closure and periprocedural complications in the multicenter CLOSURE 1 study suggest that these procedures should be performed in centres with ample expertise by an experienced team. In such centres these procedures should be considered safe and effective.

CONCLUSIONS

Percutaneous PFO closure seems to be a safe procedure when performed in a centre with adequate expertise with regard to these procedures.

Conflict of interest: none declared

References

- Larrue V, Berhoune N, Massabuau P et al. Etiologic investigation of ischemic stroke in young adults. *Neurology*, 2011; 76: 1983–1988.
- Spies C, Strasheim R, Timmermanns I et al. Patent foramen ovale closure in patients with cryptogenic thromboembolic events using the Cardia PFO occluder. *Eur Heart J*, 2006; 27: 365–371.
- Wahl A, Tony T, Meier B et al. Late results after percutaneous closure of patent foramen ovale for secondary prevention of paradoxical embolism using the amplatzer pfo occluder without intraprocedural echocardiography. *J Am Coll Cardiol Interv*, 2009; 2: 116–123.
- Post MC, Van Deyk K, Budts W. Percutaneous closure of a patent foramen ovale: single-centre experience using different types of devices and mid-term outcome. *Acta Cardiol*, 2005; 60: 515–519.
- Khairy P, O'Donnell CP, Landzberg MJ. Transcatheter closure versus medical therapy of patent foramen ovale and presumed paradoxical thromboemboli: a systematic review. *Ann Intern Med*, 2003; 139: 753–760.
- Windecker S, Wahl A, Nedeltchev K et al. Comparison of medical treatment with percutaneous closure of patent foramen ovale in patients with cryptogenic stroke. *J Am Coll Cardiol*, 2004; 44: 750–758.
- Seiler C. Wow should we assess patent foramen ovale? *Heart*, 2004; 90: 1245–1247.
- Hausmann D, Mügge A, Becht I et al. Diagnosis of patent foramen ovale by transesophageal echocardiography and association with cerebral and peripheral embolic events. *Am J Cardiol*, 1992; 70: 668–672.
- Mügge A, Daniel WG, Angermann C et al. Atrial septal aneurysm in adult patients: a multicenter study using transthoracic and transesophageal echocardiography. *Circulation*, 1995; 91: 2785–2792.
- Braun M, Glicch V, Boscheri A et al. Transcatheter closure of patent foramen ovale (PFO) in patients with paradoxical embolism: periprocedural safety and mid-term follow-up results of three different device occluder systems. *Eur Heart J*, 2004; 25: 424–430.
- Martín F, Sánchez PL, Doherty E et al. Percutaneous transcatheter closure of patent foramen ovale in patients with paradoxical embolism. *Circulation*, 2002; 106: 1121–1126.
- Windecker S, Wahl A, Chatterjee T et al. Percutaneous closure of patent foramen ovale in patients with paradoxical embolism long-term risk of recurrent thromboembolic events. *Circulation*, 2000; 101: 893–898.
- Schwerzmann M, Windecker S, Wahl A et al. Percutaneous closure of patent foramen ovale: impact of device design on safety and efficacy. *Heart*, 2004; 90: 186–190.
- Anzai H, Child J, Natterson B et al. Incidence of thrombus formation on the CardioSEAL and the Amplatzer closure devices. *Am J Cardiol*, 2004; 93: 426–431.
- Krumsdorf U, Ostermayer S, Billinger K et al. Incidence and clinical course of thrombus formation on atrial septal defect and patent foramen ovale closure devices in 1000 consecutive patients. *J Am Coll Cardiol*, 2004; 43: 302–309.
- Meissner I, Whisnant JP, Khandheria BK et al. Prevalence of potential risk factors for stroke assessed by transesophageal echocardiography and carotid ultrasonography: the SPARC study: stroke prevention: assessment of risk in a community. *Mayo Clin Proc*, 1999; 74: 862–869.
- Braun MU, Fassbender D, Schoen SP et al. Transcatheter closure of patent foramen ovale in patients with cerebral ischemia. *J Am Coll Cardiol*, 2002; 39: 2019–2025.

Analiza powikłań okołozabiegowych i późnych po przezskórnych zabiegach zamknięcia przetrwałego otworu owalnego: doświadczenia jednego ośrodka

Przemysław Węglarz¹, Ewa Konarska-Kuszevska¹, Katarzyna Spisak-Borowska², Jerzy Machowski², Agnieszka Drzewiecka-Gerber¹, Piotr Kuszevski³, Christopher L. Jackson⁵, Grzegorz Opala⁴, Maria Trusz-Gluza¹

¹Katedra i Klinika Kardiologii, Śląski Uniwersytet Medyczny, Katowice

²Oddział Neurologii, Szpital Miejski, Oświęcim

³Śląski Uniwersytet Medyczny, Katowice

⁴Katedra i Klinika Neurologii, Śląski Uniwersytet Medyczny, Katowice

⁵Bristol Heart Institute, Bristol University, Bristol, Wielka Brytania

Streszczenie

Wstęp: Przetrwwały otwór owalny (PFO) jest potencjalnym czynnikiem ryzyka udaru niedokrwiennego mózgu u osób młodych. Interwencyjnym sposobem profilaktyki wtórnej udaru mózgu u pacjentów z PFO jest jego przezskórne zamknięcie.

Cel: Celem tego prospektywnego badania była ocena bezpieczeństwa i skuteczności (brak przecieku resztkowego) przezskórnego zamykania PFO u pacjentów po przebytych kryptogennym epizodzie neurologicznym.

Metody: Zabiegowi przezskórnego zamknięcia PFO poddano 149 pacjentów (56 mężczyzn/93 kobiety) w średnim wieku 39 ± 12 lat. Wszczepienie okludera odbywało się w znieczuleniu miejscowym, pod kontrolą przezprzelykowej echokardiografii (TEE) i skopii. Po miesiącu wykonywano kontrolne badanie przezklatkowe (TTE), a po 6 miesiącach od zabiegu kontrolne badanie TEE. W przypadku obecności przecieku resztkowego badanie TEE ponawiano po następnych 6 miesiącach.

Wyniki: Skuteczne zamknięcia PFO (bez przecieku resztkowego) uzyskano u 91,3% pacjentów po 6 miesiącach i u 95,3% osób po 12 miesiącach. W 2 przypadkach obserwowano w czasie zabiegu migotanie przedsionków, które ustąpiło samoistnie. U 2 osób wystąpił krwiak w miejscu wkłucia, u 1 pacjentki powierzchowne zapalenie żył. W 1 przypadku po zabiegu stwierdzono niewielką ilość płynu w worku osierdziowym; po włączeniu niesteroidowych leków przeciwzapalnych płyn uległ resorpcji w 3. dobie hospitalizacji.

Wnioski: Przezskórne zamykanie PFO wydaje się zabiegiem bezpiecznym, jeśli jest wykonywane w ośrodku dysponującym zespołem specjalizującym się w takich interwencjach.

Słowa kluczowe: przetrwwały otwór owalny, PFO, powikłania, zabiegi zamykania

Kardiologia 2012; 70, 5: 478–484

Adres do korespondencji:

dr n. med. Przemysław Węglarz, I Katedra i Klinika Kardiologii, Śląski Uniwersytet Medyczny, ul. Ziołowa 45/47, 40–635 Katowice, e-mail: pweglarz@gmail.com

Praca wpłynęła: 05.06.2011 r. Zaakceptowana do druku: 02.11.2011 r.

Copyright © Polskie Towarzystwo Kardiologiczne